



## A CASE OF MID-FREQUENCY SENSORINEURAL HEARING LOSS

At. Vlaykov\*, V. Stoyanov

Department of Otorhinolaryngology and Ophthalmology, Faculty of Medicine, Trakia University, Stara Zagora, Bulgaria

### ABSTRACT

**Introduction:** Mid-frequency sensorineural hearing loss (MFSNHL) is an unusual audiometric finding with a debatable etiology with unclear long-term results. In general, the middle frequencies are affected first, and the process progresses slowly to include all frequencies. There are also some cases where provocative factors have been reported.

**Purpose:** The aim of the work is to present a clinical case in our practice of the rare occurrence of mid-frequency acoustic hearing loss and its diagnostic approach.

**Material and methods:** The patient has undergone a number of manual and instrumental tests to confirm or reject a specific cause of the hearing loss condition.

**Results:** A 52-year-old man was hospitalised with complaints of hearing loss for about a year, judging by the growing difficulty in making a phone call.

**Conclusions:** Generally, a U-shaped audiogram is thought to indicate hearing loss of genetic origin. However, this type of deafness is not unique to one particular type of genetic mutation. There are also numerous descriptions of non-genetic mid-frequency hearing loss in the literature. In the particular clinical case presented by us, it was concluded that this was a hearing loss, possibly of hereditary nature, after excluding another provocative cause, as well as due to anamnestic data on premature hearing loss in one of the parents.

**Key words:** mid-frequency hearing loss, U-shaped audiogram

### INTRODUCTION

For most people, sensory-neural hearing loss (SNHL) begins with the involvement of high frequencies later in individual development, which is associated with presbycusis, without proving the presence of a genetic defect.

Most forms of non-syndromic hereditary hearing loss have been described as sensory-neural - related to permanent hearing loss, caused by damage of structures in the inner ear. They mainly engage the high frequencies and the inability to perceive them or the entire frequency range resulting in total deafness.

Mid-frequency hearing loss (MFSNHL) is an unusual audiometric finding with a debatable etiology and unclear long-term results. Mid-

frequency hearing loss is described by hereditary hearing loss, which is usually autosomal dominantly transmitted. In general, the middle frequencies are affected first, and the process progresses slowly to include all frequencies later on. There are also some cases where provocative factors have been reported - intoxication, tumours, traumas, etc. [1, 2]

Non-syndromic autosomal dominant acoustic hearing loss, including midrange, and resembling on the audiogram “cookie bite” shape, U-shaped, or trough shape audiometric curve, is still a known clinical condition. A review of published reports describing this condition shows that the onset and progression of hearing loss vary across patients [3]. It is a relatively rare hearing impairment and is characterised by the inability of those affected to hear midrange sounds, although they maintain good high and low frequency perception. The condition allows the person to hear various annoying and unpleasant noises,

\*Correspondence to: *Atanas Vlaykov, PhD; Department of Otorhinolaryngology and Ophthalmology, Faculty of Medicine, Trakia University, Stara Zagora, Bulgaria, at.vlaykov@gmail.com*

but at the same time it is difficult to perform a normal conversation [4].

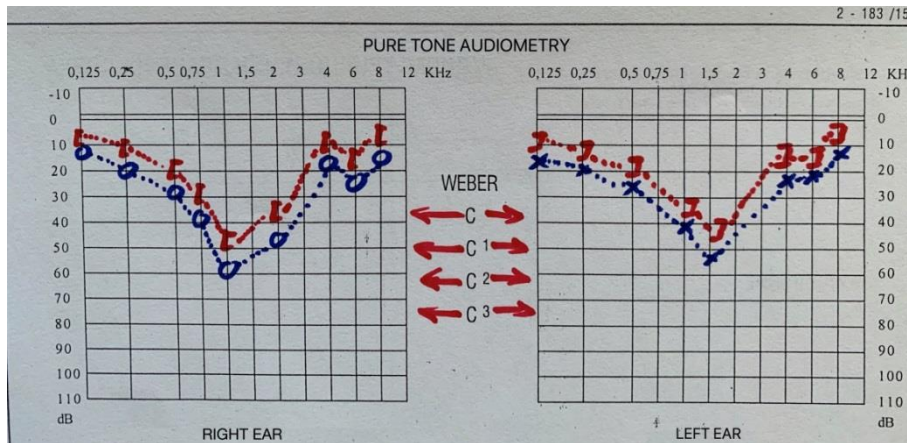
**CLINICAL CASE**

In the Clinic of ENT Diseases at University Hospital in Stara Zagora a 52-year-old man was hospitalised with complaints of hearing loss for about a year, judging by the growing difficulty in making a phone call. No tinnitus or vertigo was present. No history of mechanical, acoustic, ototoxic or barometric injury. There were no symptoms specific for systemic autoimmune diseases. He reported the premature hearing loss of his mother for no identifiable reason.

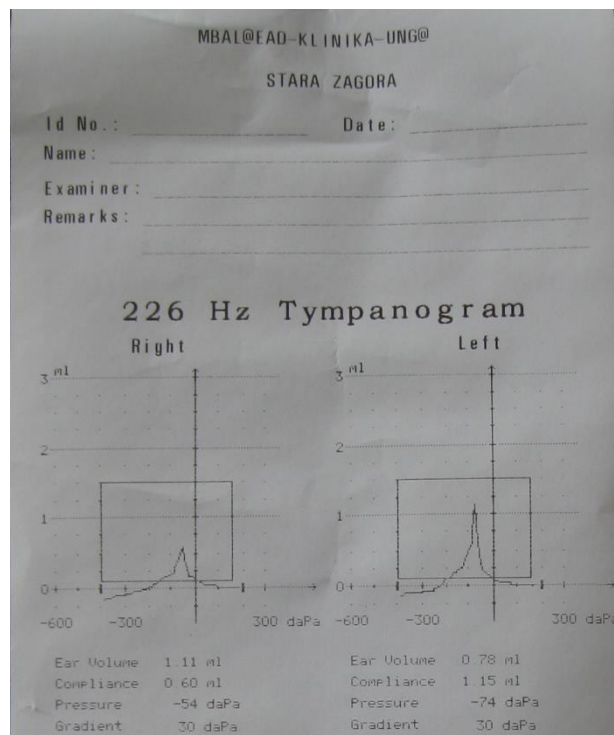
A general examination of the ears, nose and throat showed no deviation. There were no relevant data on the occurrence of genetic

syndromes. The examination of the cranial nerves showed no involvement.

Audiological tests revealed a bilateral mid-frequency, "U-shaped" configuration of sensorineural hearing loss (**Figure 1**). Tympanometry did not detect abnormalities (**Figure 2**) neither did the study of the stapedial reflex (**Figure 3**). The profile radiographs of the cervical vertebrae objectified the osteophytes of the anterior and posterior margins of the C3, C5-C7 bodies, which was rejected as the cause of the hearing changes. Nuclear magnetic resonance (NMR) of the temporal bone was normal. Blood count, ESR, and C-reactive protein were normal. After the exclusion of any kind of pathology this hearing loss was assessed as being the probable result of a hereditary condition.



**Figure 1.** Pure tone audiometry



**Figure 2.** Tympanometry

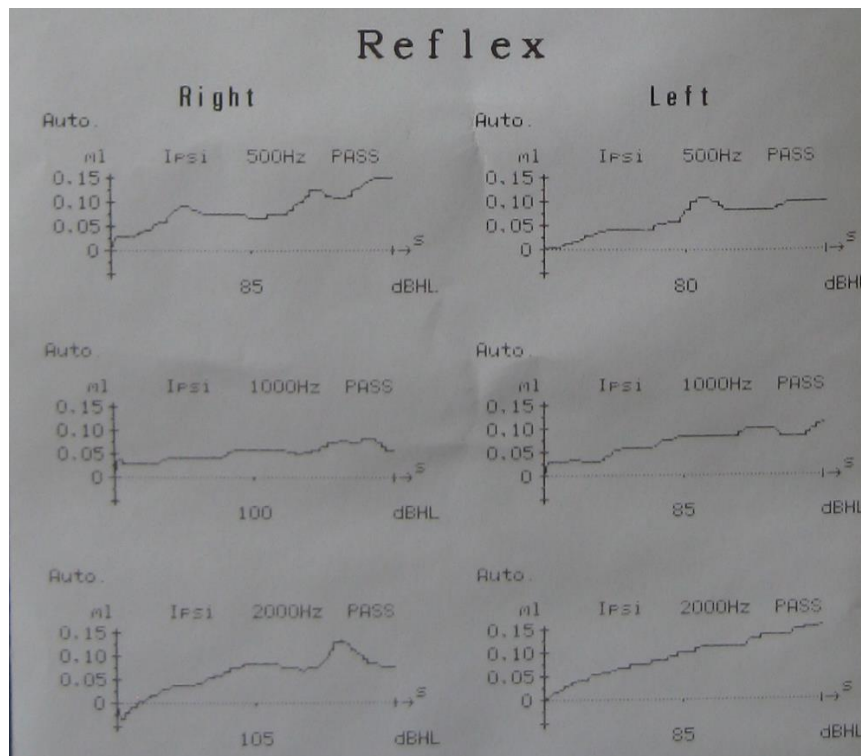


Figure 3. Stapedial reflex

## DISCUSSION

Cookie bite audiograms can be detected in both nonsyndromic and syndrome hearing loss. In support of the syndromic manifestation of the condition, "U-shaped" audiograms have been described in individuals with autosomal dominant transmitted mechanism, like Vaardenburg syndrome [5].

On the other hand, a large proportion of autosomal recessive inheritance hearing disorders are due to a gene mutation for the Connexin 26 protein, which is manifested in severe prelingual auditory hearing loss. In their study, Orzan et al. associate this mutation with mid-frequency hearing loss [6].

Saunders et al, on the other hand, report that mid-frequency "U-shaped" acoustic hearing loss has been observed in patients with sudden hearing loss due to tumours in the internal auditory canal affecting Acoustic nerve [7].

In their work, Bahmad et al. have dissected temporal bones in two people with SNHL during an autopsy. They subsequently analysed the cochlear part of the inner ear under light microscopy. The auditory receptor cells, stria vascularis and cochlear neuronal cells were evaluated in the analysis of cytochleograms. The major histopathological abnormalities that the authors describe are the loss of receptor

cells, stria vascularis and cochlear neurons in the first case and the loss of receptor cells and stria vascularis in the second case. These results are consistent with the hypothesis that dysfunction and loss of receptor cells may be the major histopathological correlate of mid-frequency hearing loss in these 2 subjects [8].

## CONCLUSIONS

In summary, it is generally believed that a U-shaped audiogram indicates hearing loss of genetic origin. Many of them are found both in autosomal dominant and recessive, nonsyndromic and syndromic hereditary hearing loss. This type of deafness is not unique to one type of genetic mutation. However, there have been reported cases of non-genetic mid-frequency hearing loss in the literature. The clinical case presented by us concluded that it was a hearing loss, probably of hereditary nature, after excluding another provocative cause, as well as due to the anamnestic data on premature hearing loss in one of the parents.

The most common option for therapeutic hearing loss in a cookie-bitten hearing is with hearing aids. Today, more sophisticated digital technologies are far better at correcting this unique type of hearing loss. Those who are equipped with hearing aids with the maximum number of channels and the ability to adjust

flexibly tend to feel significantly better than those who have the means with only a few available channels and limited tuning features. It is hoped that future developments in gene therapy capabilities can be successfully applied to treat such conditions.

#### REFERENCES

1. Liu, X., Xu, L., Nonsyndromic hearing loss: an analysis of audiograms. *Ann Otol Rhinol Laryngol*, 103:428-433, 1994.
2. Konigsmark, B., Salman, S., Haskins, H., et al., Dominant midfrequency hearing loss. *Ann Otol Rhinol Laryngol*, 79:42-53, 1970.
3. Kaksonen, R., Widen, E., Cormand, B., et al. Autosomal dominant midfrequency hearing impairment. *Scand Audiol Suppl*, 52:85-7, 2001.
4. Kunst, H., Huybrechts, C., Marres, H., Huygen, P., Van Camp, G., Cremers, C., The phenotype of DFNA13/COL11A2: nonsyndromic autosomal dominant mid-frequency and high-frequency sensorineural hearing impairment. *Am J Otol*, 2:181-7, 2000.
5. Newton, V., Hearing and Waardenburg's syndrome: implications for genetic counseling. *J Laryngol Otol*, 104:97-103, 1990.
6. Orzan, E., Polli, R., Martella, M., Vinanzi, C. et al., Molecular genetics applied to clinical practice: the Cx26 hearing impairment. *Br J Audiol*, 33:291-295, 1999.
7. Saunders, J., Luxford, W., Devgan, K. et al., Sudden hearing loss in acoustic neuroma patients. *Otolaryngol Head Neck Surg*, 113:23-31, 1995.
8. Bahmad, F., O'Malley, J., Tranebjærg, L., Merchant, S., Histopathology of Nonsyndromic Autosomal Dominant Midfrequency Sensorineural Hearing Loss. *Otol Neurotol*, 29(5):601-606, 2008.